

CONTINUING EDUCATION

A SUPPLEMENT TO

OPTOMETRIC  
Management

SEPTEMBER 2007

# Comprehensive Management of the Ocular Surface

Learn how to manage glaucoma in the dry eye patient, enhance the protective effects of the tear film, as well as treat red eyes, ocular allergy and other infections more effectively.

Supported by an unrestricted  
educational grant from

**Alcon**<sup>®</sup>

# Manage Glaucoma and Dry Eye Simultaneously

Here's how to use a variety of effective drugs to treat glaucoma, prevent IOP spikes and minimize surface inflammation.

Glaucoma typically isn't a stand-alone disease. Because most patients with glaucoma are over age 60, often they receive treatments simultaneously for other systemic health issues. Those health problems and the medications patients take to treat them can affect the status and treatment course of their glaucoma. But when patients have simultaneous ocular surface disease, the impact of medication use usually is more direct (Figure 1).

Dry eye is often a concurrent disorder with glaucoma because the risk for both conditions increases with age. In addition, some glaucoma medications or their preservatives can compromise the ocular surface — and some medications for inflammatory dry eye can raise IOP. To effectively manage patients with both problems, we need to be aggressive about long-term control of IOP while nurturing a healthy, comfortable ocular surface.

This article will discuss why ocular surface disease is prevalent among glaucoma patients and the advan-

tages of using medications containing a gentler preservative. I also will discuss ways to treat both glaucoma and dry eye simultaneously, while maintaining the highest level of ocular health.

## A likely pair

We owe the prevalence of glaucoma combined with ocular surface disease to several causes:

**1. Age-related ocular surface changes.** Between the ages of 55 and 65 when glaucoma typically is diagnosed, the ocular surface already has started an involutional decline in health independent of glaucoma. And, unfortunately, that decline continues as the patient continues to age.

We used to look at this part of the aging process as something that might not have required treatment, and we may have overlooked the roles that other factors were playing in the disease. Today, we treat the problem to achieve a healthier ocular surface and better comfort.

**2. Mechanical challenges.** Many patients with glaucoma have poor lid structure. The lid muscles are lax, making adhesion to the surface poor. These mechanical concerns impair the ability to maintain normal tear production and flow.

**3. Shared risk factors.** In addition to age, glaucoma and ocular surface disorders share some risk factors, such as smoking, use of systemic medications and underlying vascular or inflammatory disease.

**4. The toxic effects of chronic topical drug use.** We've found that chronic use of topical glaucoma therapy produces a constant low-grade toxicity to the ocular surface. And glaucoma treatment begins much earlier and lasts much longer than it used to, thanks to the revolution in our understanding of the disease's progression.

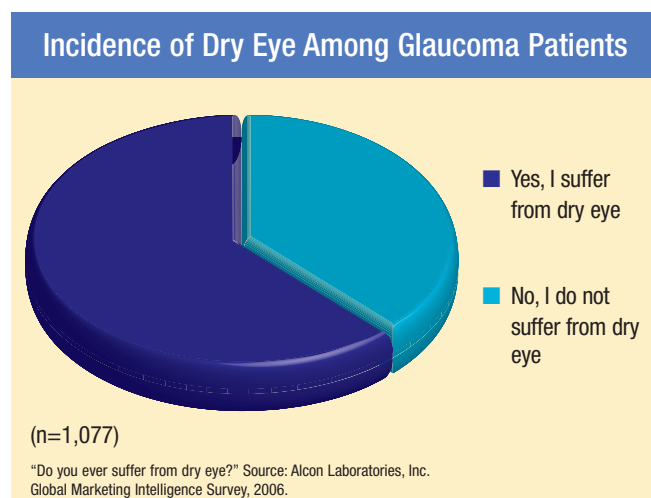


Figure 1. Most glaucoma patients suffer from dry eye, raising concerns about medication use that can further compromise the ocular surface.

By J. James Thimons, O.D., F.A.A.O.



### Treating glaucoma earlier and longer

We used to diagnose glaucoma based on elevated IOP alone, and often we waited until the visual field was compromised before we initiated therapy. Today, our approach is very different. We now understand that changes in the optic nerve precede elevated IOP and visual field loss in glaucoma progression.<sup>1</sup> In addition, advances in OCT, HRT and GDx technologies now enable us to see the fine detail of the eye's structure and detect minor changes so that we can diagnose glaucoma in its earliest stages.

This new paradigm for diagnosis means that patients with glaucoma receive regular observation and treatment for many years. In fact, patients begin treatment years or even decades earlier, which amounts to a total treatment time that is decades longer than in the past.

This duration is a challenge to us. What is the impact of chronic use of glaucoma drugs? How can we manage glaucoma effectively in concert with treatment for other health problems that likely will arise?

### Preserving the ocular surface

These are tough questions to answer. Chronic use of topical glaucoma drugs has caused problems associated with toxicity, including damage to the ocular surface. Long-term use of preserved topical anti-glaucoma drugs has been shown to compromise the conjunctiva and lacrimal gland function, as well as raise inflammatory markers on the ocular surface.<sup>2-4</sup> One of our treatment goals, then, is to maintain a healthy ocular surface over time while managing the glaucoma. One of the keys to preserving the ocular surface

### Equivalent IOP-Lowering TRAVATAN® Z Solution and TRAVATAN® Solution

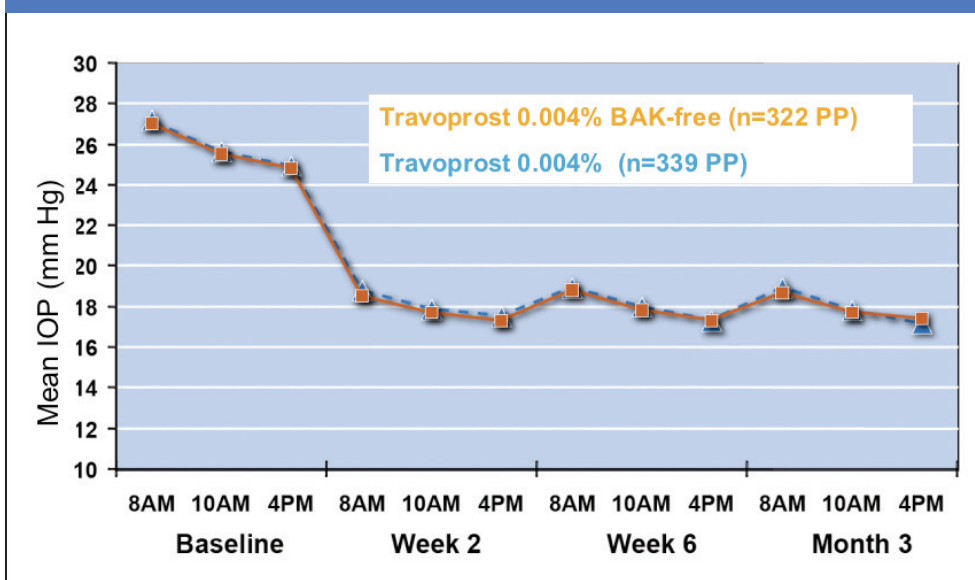


Figure 2. The BAK-free prostaglandin travoprost ophthalmic solution 0.004% (Travatan Z®) is preserved with Purite, a gentler preservative that has less deleterious effects on the corneal surface.

may be in the preservative.

Unpreserved drops cause less irritation to the ocular surface than those containing an antimicrobial preservative.<sup>5</sup> But an effective preservative is necessary for drops to remain germ-free and effective when they're used for multiple dosing.

Benzalkonium chloride (BAK) is a capable, effective antimicrobial preservative that prevents bacteria and viruses from colonizing eye drops. The preservative is used in many glaucoma medications. But as we've observed in contact lens wearers and in patients taking prostaglandins for glaucoma, chronic use of medications containing BAK eventually can harm the ocular surface and result in patient complaints.

Studies have shown that chronic use of BAK-preserved drops damages the corneal epithelium, which is critical to maintaining a healthy, stable tear film.<sup>6,7</sup> The preservative decreases the viability of surface epithelial cells — an effect we can observe with scanning electron microscopy.

What's more, patients experience dryness, irritation and inflammation, and they must continue to use



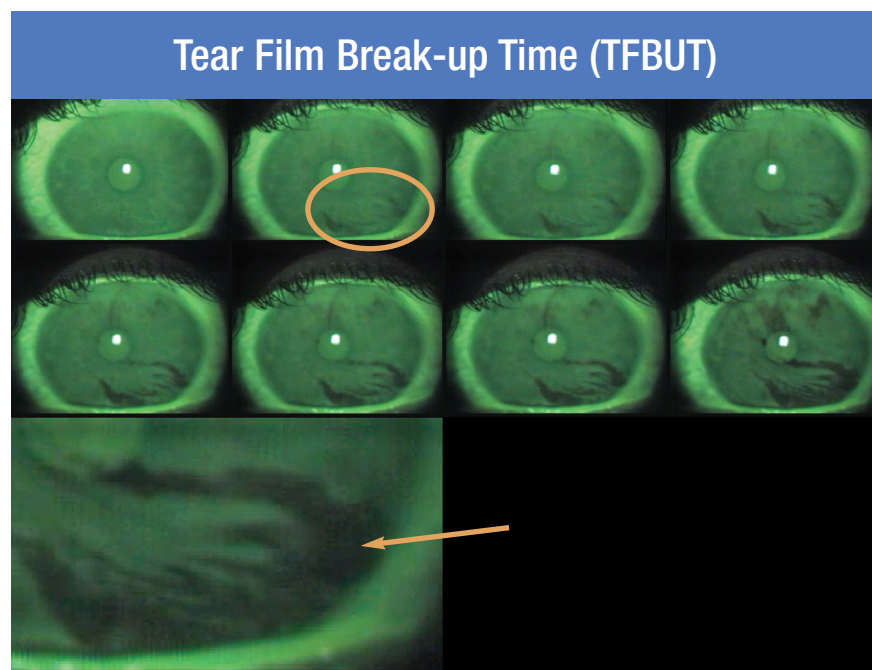


Figure 3. Lissamine green testing is performed to determine tear film break-up time (TFBUT). The test reveals dead cells on the ocular surface, validating the symptoms of dry eye.

their glaucoma medication or consider surgical intervention.

Now, we have the option of using the BAK-free prostaglandin travoprost ophthalmic solution 0.004% (Travatan Z, Alcon Laboratories Inc.). Instead of BAK, this drug is preserved with Purite, which has less deleterious effects on the corneal sur-

face<sup>8</sup> (Figure 2). The unique formulation of BAK-free travoprost is a good choice for chronic topical glaucoma treatment. It controls IOP in patients while decreasing the toxicity and ocular surface damage of BAK-preserved drops. And lower toxicity means safer long-term treatment than we had in the past.

### Starting glaucoma treatment

When I start patients on BAK-free travoprost, I explain that it (like all prostaglandins) typically will cause redness in the beginning. In fact, I frame the redness as part of the treatment's success. I tell patients, "Your eyes will become a little red, but this tells me the drops are working. Call me if you don't see redness. The body reacts fairly quickly, and the redness will go away in a few days."

Patients use the drug once a day. I recommend they use it at night because of the temporary redness. Patients return in 4 to 6 weeks so I can gauge the drug's effectiveness. Over several visits, I test the patient's IOP in the morning, late morning/early afternoon and evening to see how the drug is controlling pressure throughout the day. Travoprost maintains its IOP-lowering effect long after a patient takes the drug. It has excellent persistence of efficacy.

If I don't get the desired IOP reduction at the follow-up visit, I might switch prostaglandins, but usually I see a good response with minimal problems. For patients with previous ocular surface damage from BAK-preserved medication, it can take 3 to 4 months for the toxicity to diminish and healing to take place. At that point, I can see the effects of switching to a minimally toxic drug. Patients say they have less irritation. Later, if their IOP rises as the disease progresses, I'll add a carbonic anhydrase inhibitor (CAI), such as topical brinzolamide ophthalmic suspension 1% (Azopt, Alcon Laboratories Inc.) twice a day. CAIs have been shown to have excellent efficacy when used with a prostaglandin.

### Adding a dry eye medication

When a patient with glaucoma has symptoms of ocular surface disease, I perform a thorough assessment of his status. I ask him whether or not he has

## Shared Risk Factors for Glaucoma And Dry Eye

- Age
- Smoking
- Use of systemic medications, such as anticholinergics
- Underlying vascular or inflammatory disease

## Prevalence of Glaucoma and Dry Eye

- About one-third of women between 40 and 59 and half of patients over 65 experience symptoms of dry eye.<sup>10</sup>
- 1 in 4 ophthalmology visits is for dry eye.<sup>12</sup>
- Open-angle glaucoma affects about 2.2 million Americans.<sup>9</sup> (This number is expected to jump to 3.6 million by 2020).

any systemic diseases, such as arthritis or a thyroid disorder. I look at the lid muscle architecture and evaluate the tear meniscus to measure tear volume. I perform lissamine green testing to confirm dry eye symptoms and fluorescein testing to determine tear film breakup time (Figure 3). Elderly patients often have low-grade blepharitis contributing to their dry eye.

Also, I want to know what prescriptions and over-the-counter medications the patient uses. If a patient uses a drug that may contribute to ocular health problems, such as agents with anticholinergic activity, I want to make sure the medication is necessary before I make any adjustments to the glaucoma and dry eye treatments.

Next, I choose the treatment option that's best for the patient's individual situation. No single treatment produces the perfect ocular surface in a 75-year-old, but we can regain comfort. Younger patients usually want to begin wearing contact lenses comfortably again. Treatment options include cyclosporine ophthalmic emulsion 0.05% (Restasis, Allergan Inc.), loteprednol etabonate ophthalmic suspension 0.5% (Lotemax, Bausch & Lomb) and prednisolone acetate (Pred Forte, Allergan Inc.), as well as a lid hygiene regimen, omega-3 fatty acid supplements and punctal plugs.

Patients with minor irritation can simply use lubricating drops, but if there's inflammation, we need to bring it under control first. When I see a patient who's been taking a BAK-preserved glaucoma medication for a long time, often I start treating the inflamed state. The problem with steroids is that they can elevate IOP over time, and this problem is more

common in patients with glaucoma.

Therefore, I typically use loteprednol for inflammatory dry eye because it's safer than the alternatives for reducing inflammation. Many doctors don't use loteprednol out of concern that it may cause an inappropriate spike in IOP, but the IOP effects are minimal in short-term intervention. Research shows there's no significant change in IOP after using the drug for 1 month,<sup>11</sup> and I order the drug for only 1 week to 10 days to quiet inflamed eyes. The drug also has no interactions with glaucoma drugs when used for a short period. However, with end-stage glaucoma or with a patient who's had an IOP response in the past, you'll need to watch closely for any small spike in pressure that could be detrimental.

### Making it all work

Effective treatment for patients with glaucoma and dry eye requires a smart approach, using low-toxicity glaucoma medications and anti-inflammatories that have little impact on IOP. Together, these medications can help us manage glaucoma while making the ocular surface healthier. Now that we can diagnose glaucoma earlier than ever before, we need to manage the comfort issues that may arise over the lifetime of the patient. **OM**

---

J. James Thimons, O.D., F.A.A.O., is medical director of Ophthalmic Consultants of Connecticut in Fairfield and clinical professor at Pennsylvania College of Optometry, Elkins Park. He's also the chairman of the National Glaucoma Society; [nationalglaucomasociety.org](http://nationalglaucomasociety.org).

#### References

1. Kourosh M, Bowd C, Weinreb RN, et al. Retinal nerve fiber layer thickness measurements with scanning laser polarimetry predict glaucomatous visual field loss. *Am J Ophthalmol*. 2004;138:592-601.
2. Nuzzi R, Finazzo C, Cerruti A. Adverse effects of topical antiglaucomatous medications on the conjunctiva and the lachrymal response. *Int Ophthalmol*. 1998;22:31-35.
3. Hong S, Lee CS, Seo KY, et al. Effects of topical antiglaucoma application on conjunctival impression cytology specimens. *Am J Ophthalmol*. 2006;142:185-186.
4. Baudouin C, Liang H, Hamard P, et al. The ocular surface of glaucoma patients treated over the long term expresses inflammatory markers related to both T-helper 1 and T-helper 2 pathways. *Ophthalmology*. 2007 May 25; [Epub ahead of print].
5. Jaenen N, Baudouin C, Pouliquen P, et al. Ocular symptoms and signs with preserved and preservative-free glaucoma medications. *Eur J Ophthalmol*. 2007;17:341-349.
6. Yee RW, Norcom EG, Zhao XC. Comparison of the relative toxicity of travoprost 0.004% without benzalkonium chloride and latanoprost 0.005% in an immortalized human cornea epithelial cell culture system. *Adv Ther*. 2006;23:511-519.
7. Whitson JT, Cavanagh HD, Lakshman N, et al. Assessment of corneal epithelial integrity after acute exposure to ocular hypotensive agents preserved with and without benzalkonium chloride. *Adv Ther*. 2006;23:663-671.
8. Noecker RJ, Herrygers LA, Anwaruddin R. Corneal and conjunctival changes caused by commonly used glaucoma medications. *Cornea*. 2004;23:490-496.
9. The Eye Diseases Prevalence Research Group. Prevalence of open-angle glaucoma among adults in the United States. *Arch of Ophthalmol*. 2004;122:532-538.
10. National Drug Treatment Information (NDTI) Sample Data. 2004-2005:701-702.
11. Pflugfelder SC, Maskin SL, Anderson B, et al. A randomized, double-masked, placebo-controlled, multicenter comparison of loteprednol etabonate ophthalmic suspension, 0.5%, and placebo for treatment of keratoconjunctivitis sicca in patients with delayed tear clearance. *Am J Ophthalmol*. 2004;138:444-457.
12. O'Brien PD, Collum LM. Dry eye: diagnosis and current treatment strategies. *Curr Allergy Asthma Rep*. 2004;4:314-319.

# Understanding the Link Between Tear Film Stability and Ocular Surface Health

**Learn how to enhance the protective function of the tear film to treat and manage dry eye more effectively.**

Dry eye syndrome (DES) or ocular surface disease (OSD) is an increasingly common, though often under-diagnosed group of conditions that present with diverse and sometimes confusing signs and symptoms.<sup>1,2</sup> Dry eye negatively affects both visual and general quality of life.<sup>3,4</sup> Patients suffering from OSD may present with a variety of complaints, including mild burning, photophobia, blurred vision, stinging, grittiness, epiphora, tired eyes and the inability to perform sustained visual tasks.<sup>5</sup> The goal of dry eye therapy is to improve the comfort and health of the ocular surface and give patients the ability to function.

In this article, I will discuss the importance of determining the etiology of dry eye, the relationship between blinking and tear film stability and the recent research on the advantages of the latest artificial tears in the treatment and management of DES.

## Diagnosing dry eye syndrome

The differential diagnosis of dry eye can be a complex and challenging task; there are numerous underlying causes, and the severity of the reported symptoms often fails to correlate with observed signs and test results. Individuals with mild DES actually may be more symptomatic than those with advanced disease; this is believed to be due to gradual loss of corneal sensation secondary to damage of the ocular surface.<sup>6</sup> Determining the etiology of dry eye is crucial to prescribing the proper therapy.

The 1995 National Eye Institute (NEI) Industry Dry Eye Workshop presented an exhaustive summary of the multiple etiologies of dry eye broken down into two main categories: aqueous layer tear deficient dry eye and evaporative dry eye.<sup>7</sup> Tests that help to distinguish between the two categories include fluorescein and lissamine green staining, Schirmer test, meibomian gland evaluation, tear film break-up time (TFBUT) and a dry eye questionnaire, such as the one proposed by McMonnies and Ho.<sup>7-9</sup> The

information derived from these tests helps practitioners identify the primary cause(s) of dry eye, and hence, design a program of treatment and rehabilitation for the ocular surface. Although there's no known cure for dry eye, we can prescribe multiple palliative therapies that enhance patient comfort and vision, and in some cases, may improve the health and quality of the ocular surface.

## Managing dry eye

To appropriately manage DES, we must understand the dynamic relationship between blinking and tear film stability. Immediately after blinking, there's a period of dissolution and disorganization of the tear film. The tear film reconstitutes itself and protects the ocular surface from damage secondary to dryness. The time between blinks is known as the "blink interval," and this period is variable. Nakamori and colleagues<sup>10</sup> showed that the maximum blink interval depends on the status of the ocular surface.

Optimal ocular surface health is possible only when it's continuously protected by the tear film. The ocular protection index (OPI) compares the relationship between the TFBUT and the blink interval. The ideal situation (positive OPI) would be for tears to remain stable covering the ocular surface for the entire interval between blinks. If the tears break up between blinks, there's a period during which the ocular surface is unprotected; the OPI in this situation is said to be negative. A consistently negative OPI results in an unprotected ocular surface, and may lead to subsequent ocular surface damage<sup>11</sup> (Figure 1).

Factors that hasten tear film break-up include the loss of ocular surface integrity, alteration of tear components and reduced tear film volume. However, we can reduce these effects by prescribing an appropriate artificial tear product.<sup>12</sup> There's a plethora of artificial tear products

By William D. Townsend, O.D.



available today. These formulations vary widely depending on the individual components used to create the drops. Systane has a unique formula that has been shown to effectively reverse staining secondary to OSD.

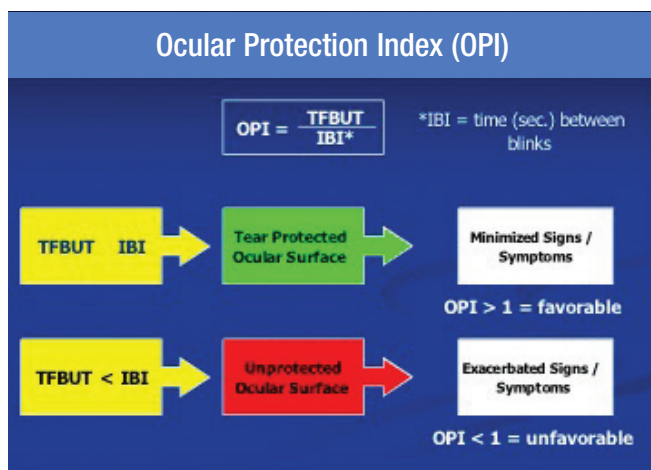


Figure 1. The ocular surface protection index (OPI) compares the relationship between the tear film break-up time and the blink interval.

### Comparing artificial tear types

A logical question would be, "What are the differences between artificial tears?" Key issues in the formulation of artificial tears include preservatives, demulcents, ionic characteristics, bioadherence and residence time. Göbbels and Spitznas<sup>13</sup> reported that it was better for patients with DES not to use any artificial tear drops than to use drops preserved with benzalkonium chloride. Now that so many modern tear substitutes are preserved with eye-friendly preservatives, such as Polyquad or Purite, or are available in nonpreserved form, there's simply no reason to prescribe a BAK-preserved dry eye preparation.

Ophthalmic demulcents are compounds used to relieve pain in inflamed or irritated mucous membranes and to wet the ocular surface. Systane contains propylene glycol (PG), a small molecule that exerts its wetting effect quickly. The second demulcent found in Systane, polyethylene glycol 400 (PEG), is a large molecule demulcent that wets the surface layer and continues to do so for a longer period of time.

Ionic characteristics have a significant impact on polymers. A good example are the demulcents PEG and PG, which are nonionic and not affected by ions present in tears. Some demulcents, such as carboxymethylcellulose, are degraded when exposed to increased ion concentrations.<sup>14</sup> Residence time is the period during which

a molecule is present in tissue, and this property is important in managing chronic conditions such as OSD. In a study by Paugh and colleagues,<sup>15</sup> Systane had a clinically significant advantage in residence time when compared to other artificial tear preparations.

To understand the mechanism by which Systane exerts its effects on the eye, it's crucial to appreciate the influence of pH on its structure. The pH of tears varies widely; in normal, non-dry eye patients, it's around 7.5, but in individuals with dry eye it may be as high as 7.9.<sup>16</sup> Systane contains borate ions and the polymer HP-guar, a water-soluble polysaccharide that displays high viscosity even in low concentrations.<sup>17</sup> In the bottle at a pH of 7, borate and HP-guar interact minimally to form a loosely cross-linked meshwork. When Systane is exposed to the higher pH of the ocular surface, bonds between borate and HP-guar are enhanced in a pH-induced reaction that transforms Systane into a stable, enduring polymer gel matrix. Systane exhibits strong bioadherence for the ocular surface, especially in areas where glycocalyx is damaged or absent. The demulcent molecules PEG and PG are bound within the HP-guar-based gel matrix.

Studies<sup>15,16</sup> confirm that Systane lubricates the interface between the ocular surface and the eyelids to reduce friction that occurs with each blink. Studies also reveal that consistent use of Systane improves tear film stability, protects the surface and facilitates restoration of ocular surface health.

### Comparing the Latest Artificial Tears

In a recent study,<sup>11</sup> Abelson and colleagues evaluated the effects of Systane and Optive (Allergan Inc.) on TFBUT over an interval of 90 minutes. Forty-two subjects were enrolled in the single center, double-masked, randomized, crossover clinical study. All of the subjects had a deficient OPI (< 1.00), and all completed the study.

At the first visit, TFBUT was measured and patients instilled one drop of Systane or Optive into both eyes. TFBUT measurements were obtained at 5, 10, 15, 20, 30, 45, 60 and 90 minutes post-instillation. The TFBUT procedure was repeated at a second visit approximately 1 week later during which time patients used the alternate artificial tear. The results of this study showed that both drops extended TFBUT from baseline through 20 minutes (Figure 2). This period, known as the "bulking phase," is commonly seen with many artificial tear



preparations. However, after instillation of Optive beginning at 30 minutes and for all later measurements, TFBUT was reduced compared with the baseline value. This second phase is known as the “tear-sustaining phase,” and reflects the product’s long-term ability to protect the ocular surface.

Systane extended TFBUT compared with baseline throughout the duration of the study and was associated with increased TFBUT between 30 and 90 minutes. This effect appears to result from restructuring of the tear film during the tear-sustaining phase. Analysis of the area under the TFBUT curves for the entire 90-minute evalu-

ation confirmed that Systane statistically significantly extended TFBUT when compared to Optive ( $P < 0.05$ ). Findings for each assessment time showed the difference between the two products was primarily due to the superiority demonstrated by Systane during the tear-sustaining phase. At 45, 60 and 90 minutes post instillation, the difference between Systane and Optive in change from baseline TFBUT significantly favored Systane ( $P < 0.05$ ).<sup>18</sup> This study provides objective evidence of the benefits realized from the surface-reparative characteristics of Systane.<sup>18</sup>

### Manageable challenge

Ocular surface disease is a group of common conditions that can be especially challenging. Clinical signs and symptoms may not correlate well or at all. Therefore, it’s incumbent upon practitioners to investigate the primary cause or causes of the patient’s complaints and understand the relationship between the blink and tear film stability so they can treat and manage the disease more effectively. In addition, they’ll need to keep abreast of the latest research on the unique ophthalmic preparations available and formulated to stabilize the tear film and restore the ocular surface to optimal health. **OM**

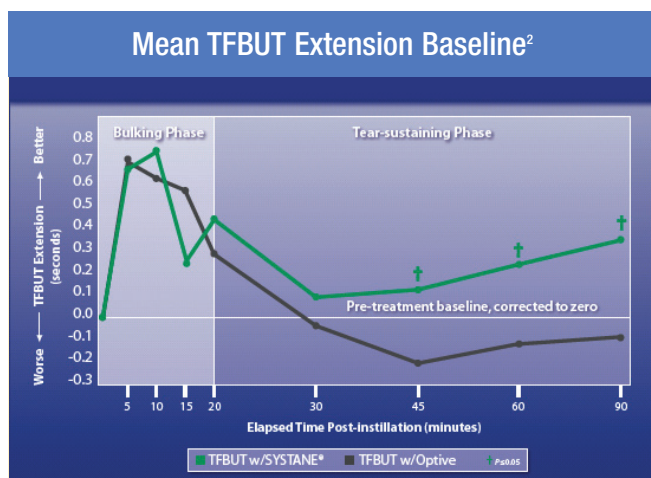


Figure 2. A study evaluating the effects of Systane and Optive on TFBUT, showed that Systane extended TFBUT between 30 and 90 minutes.

William D. Townsend, O.D., practices at Advanced Eye Care, Canyon, Texas, and is an adjunct faculty member at University of Houston College of Optometry.

### References

- Baum J, Foulks G, Lemp MA. What's in a name? *Cornea*. 2006;25:871-872.
- Asbell PA. Increasing importance of dry eye syndrome and the ideal artificial tear: consensus views from a roundtable discussion. *Curr Med Res Opin*. 2006;22:2149-2157.
- Miljanovic B, Dana R, Sullivan DA, Schaumberg DA. Impact of dry eye syndrome on vision-related quality of life. *Am J Ophthalmol*. 2007;143:409-415.
- Mertzani P, Abetz L, Rajagopalan K, et al. The relative burden of dry eye in patients' lives: comparisons to a U.S. normative sample. *Invest Ophthalmol Vis Sci*. 2005;46:46-50.
- Lemp MA. Report of the National Eye Institute/Industry workshop on Clinical Trials in Dry Eyes. *CLAO J*. 1995;21:221-232.
- Adatia FA, Michaeli-Cohen A, Naor J, et al. Correlation between corneal sensitivity, subjective dry eye symptoms and corneal staining in Sjögren's syndrome. *Can J Ophthalmol*. 2004;39:767-771.
- Nichols KK. Patient-reported symptoms in dry eye disease. *Ocul Surf*. 2006;4:137-145.
- McMonnies CW, Ho A. Patient history in screening for dry eye conditions. *J Am Optom Assoc*. 1987;58:296-301.
- McMonnies CW, Ho A. Responses to a dry eye questionnaire from a normal population. *J Am Optom Assoc*. 1987;58:588-591.
- Nakamori K, Odawara M, Nakajima T, et al. Blinking is controlled primarily by ocular surface conditions. *Am J Ophthalmol*. 1997;124:24-30.
- D'Arienzo P, Ousler GW, Schindelar MS. A comparison of two marketed artificial tears in improvement of tear film stability as measured by tear film break-up time (TFBUT) and ocular protection index (OPI). Poster presented at the 2007 Tear Film and Ocular Surface Society Meeting, Taormina, Sicily.
- Christensen MT, Stein JM, Stone RP, Meadows DL. Evaluation of the effect on tear film break-up time extension by artificial tears in dry eye patients. Presented at the 23rd Biennial Cornea Research Conference, Boston, Oct. 3-4, 2003.
- Göbbels M, Spitznas M. Effects of artificial tears on corneal epithelial permeability in dry eyes. *Graefes Arch Clin Exp Ophthalmol*. 1991;229:345-349.
- Ueno T, Yokota S, Kitaoka T, Wariishi H. Conformational changes in single carboxymethylcellulose chains on a highly oriented pyrolytic graphite surface under different salt conditions. *Carbohydr Res*. 2007;342:954-960.
- Paugh, JR, Nguyen, AL, Meadows, D, Christensen. The residence time of artificial tears in dry eye subjects. Presented at the American Academy of Optometry Annual Meeting, San Diego, December 2005. E-abstract #050062.
- Yamada M, Mochizuki H, Kawai M, et al. Fluorophotometric measurement of pH of human tears in vivo. *Curr Eye Res*. 1997;16:482-486.
- Christensen MT, Cohen S, Rinehart J, et al. Clinical evaluation of an HP-guar gellable lubricant eye drop for the relief of dryness of the eye. *Curr Eye Res*. 2004;28:55-62.
- Gifford P, Evans BJ, Morris J. A clinical evaluation of Systane. *Cont Lens Anterior Eye*. 2006;29:31-40.



By Alan G. Kabat, O.D., F.A.A.O.



# Diagnosing and Treating The Inflamed Red Eye

**Not all red eyes have the same etiology. Here's how to distinguish between the various ocular conditions and treat each one effectively.**

The clinical term “red eye” may describe any number of inflammatory ocular conditions. These may range greatly in etiology and severity from benign, common disorders, such as acute allergic conjunctivitis, to potentially sight-threatening maladies like uveitis and corneal ulcers. While each of these conditions may manifest as distinct clinical presentations, all red eyes generally warrant prompt evaluation and intervention. And patients with these disorders want prompt relief of their signs and symptoms.

Making distinctions between the various ocular inflammatory conditions is the first crucial step in selecting the most efficacious therapy for proper management.

In this article, I'll review some of the inflammatory ocular conditions that cause red eyes and discuss today's standard of care for treating them effectively.

## Viral conjunctivitis

Viral conjunctivitis is a relatively common condition in clinical practice. In a recent study<sup>1</sup> conducted at Wills Eye Hospital, 62% of patients presenting with acute infectious conjunctivitis tested positive for adenovirus. The condition may be unilateral at onset, but often it spreads to the fellow eye shortly after presentation. Symptoms consist of a thick serous discharge, diffuse bulbar hyperemia, chemosis of the conjunctiva and lid edema. Follicles may be present, as well as preauricular and/or submandibular lymphadenopathy, depending on the type and severity of the infection.

In mild, nonspecific viral conjunctivitis, the eye is modestly hyperemic and chemotic, giving it an appearance that's consistent with the generic term pinkeye. Rarely, patients report pain. They present most commonly with mild photophobia and persistent tearing. A recent history of a cold or flu often is associated with the infection. More severe presentations can include pharyngoconjunctival fever (PCF) and epidemic keratoconjunc-

tivitis (EKC). PCF is most common in children and is characterized by a high fever, sore throat, acute upper respiratory infection and follicular conjunctivitis. EKC represents the most severe form of adenoviral conjunctivitis. Signs include inferior follicular conjunctivitis, significant hyperemia, eyelid edema and associated lymphadenopathy. Corneal involvement also is common, with subepithelial infiltrates evident in most cases within the first 3 weeks of the disease.<sup>2</sup> More severe presentations involve hemorrhagic conjunctivitis, anterior uveitis and inflammatory pseudomembrane. The term “epidemic” refers to EKC's unparalleled contagious nature; the condition easily is passed between family members, school children and office workers.

While all cases of viral conjunctivitis are self-limiting, severe presentations, such as EKC, can compromise the ocular surface and cause significant discomfort. Unfortunately, adenoviruses are invulnerable to antiviral agents, such as trifluridine ophthalmic solution 1% (Viroptic, King Pharmaceuticals). Cold compresses, ocular lubricants and topical nonsteroidal anti-inflammatory drugs (NSAIDs) can be used as supportive therapy during the acute phase of the disease. You can suppress severe inflammation with the use of topical corticosteroids, such as prednisolone acetate ophthalmic suspension, USP 1% (Pred Forte) q.i.d. Contrary to popular belief, there's no evidence suggesting that the judicious use of topical corticosteroids worsens the prognosis for adenoviral conjunctivitis.<sup>2</sup> In EKC, the administration of corticosteroids reduces lymphocytic infiltration and hastens the recovery of vision and comfort secondary to corneal infiltration. Pseudomembranes, which consist of coagulated exudate adherent to the inflamed conjunctiva, should be removed. You can achieve this best by using a moistened cotton-tipped applicator or forceps with the biomicroscope.

## Bacterial conjunctivitis

Bacterial conjunctivitis is another condition we see often in clinical practice. It's usually bilateral, although the patient's history might suggest that it began in one eye before developing in the other. Like patients with viral conjunctivitis, those with bacterial conjunctivitis may report mild photophobia and discomfort. Pain isn't typical. Biomicroscopy reveals acute hyperemia involving the conjunctival and episcleral vessels. Typically, there's more hyperemia and inflammation inferiorly than superiorly. This occurs because the excreted bacterial toxins accumulate inferiorly due to gravity. Punctate epitheliopathy of the cornea also is common in bacterial conjunctivitis. However, the hallmark of the condition is accumulation of a thick, yellowish mucopurulent discharge (Figure 1). Commonly, patients complain of their eyelids and eyelashes being glued shut with this discharge upon waking. Involvement of the preauricular lymph nodes, however, isn't characteristic of bacterial conjunctivitis.

Ubiquitous gram-positive bacteria, especially *Staphylococcus aureus*, *Staphylococcus epidermidis* and *Streptococcus pneumoniae*, cause the vast majority of bacterial ocular infections in adults. Whereas, in children, gram-negative organisms, such as *Haemophilus influenzae*, are the more common culprits.

Treatment for bacterial conjunctivitis consists of broad-spectrum antibiotics. Quickly eradicating the pathogen is important. The pathogen creates unpleasant symptoms in patients, and it's also highly contagious. No other incident underscores that fact better than the outbreak of *Streptococcus pneumoniae* conjunctivitis at Dartmouth College, Hanover, N.H., which affected 698 students during the first 3 months of 2002.<sup>3</sup>

When selecting an antibiotic, it's important to choose

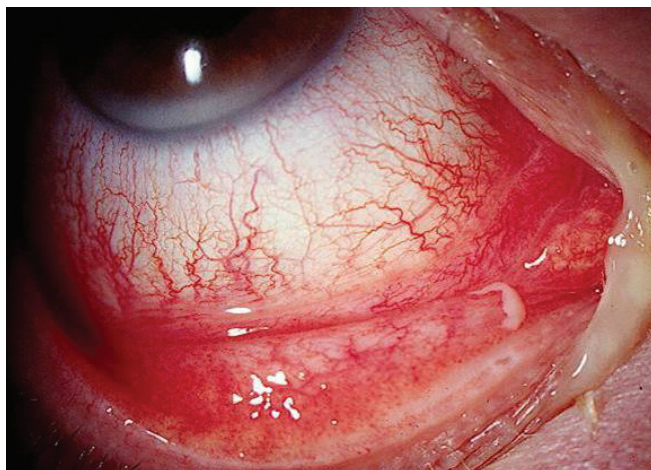


Figure 1. Bacterial conjunctivitis warrants aggressive management with a fourth-generation fluoroquinolone.

a drug that has broad-spectrum activity and specific efficacy among the more ubiquitous, gram-positive organisms. Today, our best options are the fourth-generation fluoroquinolones gatifloxacin ophthalmic solution 0.3 % (Zymar, Allergan Inc.) and moxifloxacin 0.5 % (Vigamox, Alcon Laboratories Inc.). Studies suggest that these agents provide superior antibiosis compared with earlier-generation fluoroquinolones, and they're less susceptible to bacterial resistance.<sup>4</sup> In fact, the fourth-generation fluoroquinolones have been shown to have the broadest and most rapid efficacy of any topical antibiotic on the market today.<sup>5,6</sup> Of all the commercially available fluoroquinolones, moxifloxacin offers the most convenient dosing schedule: three times a day for 7 days. Usually, patients begin to show a response within 24 to 48 hours and may be symptom-free by the fourth day of treatment.

## Blepharokeratoconjunctivitis

While both viral and bacterial conjunctivitis present with acute symptoms, some red eyes are more chronic in nature. Low-grade inflammation secondary to bacterial overgrowth on the lids may lead to blepharokeratoconjunctivitis, a condition marked by red, thickened lid margins, conjunctival hyperemia (especially inferiorly) and mild punctate epitheliopathy. Discharge is characteristically absent in blepharokeratoconjunctivitis, but patients may be highly symptomatic with crusting of the eye lashes, lid discomfort, foreign body sensation and ocular burning. Although etiologically chronic, this condition may present with acute exacerbated symptoms.

Cases of mild blepharitis often respond well to a detergent-based lid hygiene scrub and/or an antibiotic ointment, such as erythromycin or tobramycin 0.3%. The goal isn't to eradicate the normal ocular flora but to maintain control and reduce the bacterial exotoxins on the ocular surface. More severe cases of blepharokeratoconjunctivitis usually require the addition of a potent corticosteroid. In these instances, a combination drug, such as tobramycin 0.3% with dexamethasone 0.1% (TobraDex, Alcon Laboratories Inc.), used three to four times a day can be very effective in addressing both bacterial overgrowth and ocular surface inflammation. Combination drugs are easier to use and typically cost less than each of the medications sold separately.

## Bacterial keratitis

Of all the acute red eye presentations, bacterial keratitis has, perhaps, the greatest potential to cause visual morbidity. Unmanaged bacterial infections of the cornea

can lead to scarring and even ocular perforation. Patients with bacterial keratitis typically have acute pain and profound, diffuse ocular hyperemia. A mild degree of purulent discharge may be present, but usually it's not clinically significant. Using a biomicroscope, you'll notice these patients will have a focal accumulation of white blood cells (i.e., infiltrate) at the level of the corneal stroma with an overlying epithelial defect of approximately the same size. By definition, we refer to this finding as a corneal ulcer (Figure 2). A concurrent anterior chamber reaction is almost always seen in bacterial keratitis.

Corneal ulcers caused by bacterial pathogens can result from trauma, poor hygiene and poor contact lens care. The most common organisms associated with bacterial keratitis are the gram-positive strains of *Staphylococcus* and *Streptococcus*. However, gram-negative bacteria also may be present. Organisms such as *Pseudomonas aeruginosa*, which are less common, tend to produce significantly more acute and severe cases of the infection. It's important to perform corneal scrapings to obtain cultures and perform bacterial sensitivity testing especially in cases of severe, central ulcers, ulcers showing impending perforation or ulcers that are unresponsive to initial therapy. But regardless of the underlying pathogen, you must treat bacterial keratitis promptly and aggressively to prevent clinical progression and vision loss.

Currently, the use of topical fluoroquinolones is the standard of care for managing bacterial keratitis. Ciprofloxacin hydrochloride 0.3% (Ciloxan, Alcon Laboratories Inc.) and ofloxacin ophthalmic solution 0.3% (Ocuflox, Allergan Inc.) are the only commercially available drugs approved by the FDA for this purpose. Yet, because of the overwhelming scientific evidence, a

significant percentage of today's eyecare providers are using fourth-generation fluoroquinolones as first-line therapy for bacterial ulcers. Numerous reported cases have shown that drugs such as moxifloxacin are exceedingly effective at managing bacterial keratitis, even cases of severe, *Pseudomonas*-induced ulcers.<sup>7,8</sup>

While there's no universally accepted regimen for managing bacterial keratitis with fourth-generation fluoroquinolones, there are two key concepts practitioners should consider. First, always begin treatment with a loading dose. You can accomplish this by instilling three to five drops of the drug spaced 1 to 5 minutes apart in your office. Second, remember that antibiotic dosing must be frequent and commensurate with the severity of the bacterial ulcer. This means you should use the medication every 15 minutes to an hour throughout the first day or so. Then you can decrease the dose in accordance with how quickly the infection resolves. Topical antibiotics should never be instilled less than four times a day, since doses below the lethal level can lead to bacterial mutation and resistance.

Address concurrent ocular inflammation with a strong cycloplegic like homatropine 5% ophthalmic solution (Isopto Homatropine, Alcon Laboratories Inc.) or scopolamine 0.25% ophthalmic solution (Isopto Hyoscine, Alcon Laboratories Inc.) two to three times a day. The use of topical corticosteroids for corneal ulcers remains highly controversial. Historically, clinicians have avoided steroid use in bacterial keratitis for fear that suppressing the immune response would worsen the infection. However, when used judiciously along with a highly effective antibiotic, corticosteroids can hasten recovery and prevent or diminish scar formation, which can potentially improve visual outcomes.<sup>8,9</sup>

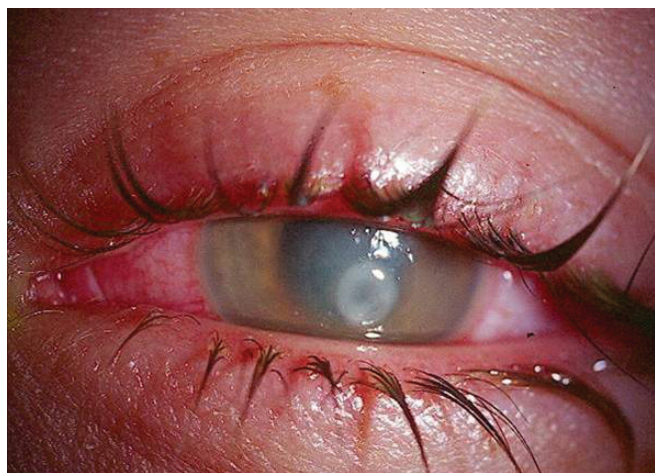

Figure 2. Corneal ulcers, such as this one, in contact lens wearers may be due to *Pseudomonas aeruginosa*.

### Viral (herpetic) keratitis

The herpes simplex virus (HSV) also is a well-known cause of corneal pathology. HSV keratitis commonly presents as a unilateral red eye with variable pain or irritation. Photophobia and epiphora are common, but vision usually isn't severely affected. The hallmark of HSV infection is a dendritic epithelial ulcer that often begins as a nondescript punctate keratopathy, but quickly coalesces into the familiar branching pattern that stains brightly with fluorescein dye (Figure 3). The leading edges of the ulcer also stain with rose bengal or lissamine green dye. Common sequelae may include corneal edema, lid swelling and anterior uveitis. But unlike bacterial keratitis, white blood cells rarely infiltrate the stroma.



HSV keratitis may present with corneal hypoesthesia, a notably diminished pain response, even in the presence of severe ulceration and inflammation. You can detect hypoesthesia simply by stroking the involved cornea with a cotton-tipped applicator and comparing the sensitivity to that of the fellow eye.

Management of HSV keratitis involves the use of trifluridine. Dosing is every 2 hours up to nine times a day until the ulcer shows signs of regression. At that point, you should decrease the medication to four times a day for another 5 days, or until reepithelialization is complete. As adjunctive therapy, some clinicians advocate corneal debridement of the ulcer to help eliminate the active, shedding virus.

One of the more serious contraindications associated with managing HSV keratitis is the use of topical corticosteroids. Steroids suppress the immune response and

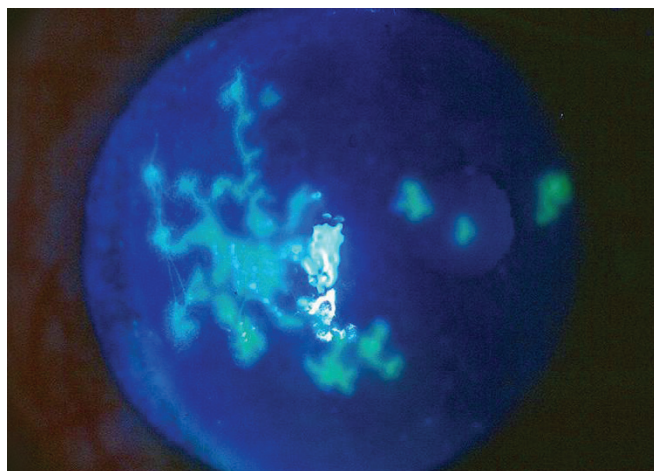


Figure 3. A classic, dendritic epithelial ulcer associated with herpes simplex virus (HSV) keratitis.

cause greater replication of the virus, which could prolong the disease and possibly induce stromal ulceration and scarring. Corticosteroids may be used judiciously once the ulcer has begun to respond to local antiviral therapy. But this is usually necessary only in cases of severe, concurrent uveitis.

Patients who have trouble using topical agents, such as children or adults with dexterity issues, can take 400 mg of oral acyclovir (Zovirax, GlaxoSmithKline) five times per day as a viable alternative.<sup>10</sup> Acyclovir also may be beneficial as a prophylactic measure. The Herpetic Eye Disease Study concluded that 400 mg of oral acyclovir twice daily can reduce the recurrence of HSV dendritic keratitis by about 36%.<sup>11</sup>

### Staying abreast

Because there are so many types of inflammatory ocular conditions that cause red eye — and many drugs with which to treat and manage them — it's important for clinicians to be able to determine the various etiologies and keep abreast of the latest therapies. Prompt, aggressive treatment of infectious and inflammatory conditions is imperative, as this ensures the best visual outcomes for patients. **OM**

---

Alan G. Kabat, O.D., F.A.A.O., is an associate professor at Nova Southeastern University College of Optometry in Fort Lauderdale, where he also serves as an attending physician at The Eye Care Institute. He lectures regularly to national and international audiences on ocular and oculsystemic disease.

### References

1. Sambursky RP, Fram N, Cohen EJ. The prevalence of adenoviral conjunctivitis at the Wills Eye Hospital Emergency Room. *Optometry*. 2007;78:236-239.
2. Kaufman, HE. Treatment of viral diseases of the cornea and external eye. *Prog Retin Eye Res*. 2000;19:69-85.
3. Martin M, Turco JH, Zegans ME, et al. An outbreak of conjunctivitis due to atypical *Streptococcus pneumoniae*. *N Engl J Med*. 2003;348:1112-1121.
4. Zhao X, Xu C, Domagala JD, et al. DNA topoisomerase targets of the fluoroquinolones: a strategy for avoiding bacterial resistance. *Proc Natl Acad Sci USA*. 1997;94:13991-13996.
5. Mather R, Karenchak LM, Romanowski EG, et al. Fourth-generation fluoroquinolones: new weapons in the arsenal of ophthalmic antibiotics. *Am J Ophthalmol*. 2002;133:463-466.
6. Esposito S, Noviello S, Ianniello F. Comparative in vitro activity of older and newer fluoroquinolones against respiratory tract pathogens. *Chemotherapy*. 2000;46:309-314.
7. Katz H. Successful treatment of a *Pseudomonas aeruginosa* corneal ulcer in a human patient with moxifloxacin 0.5% (Vigamox). Presented at the 22nd Congress of the European Society of Cataract and Refractive Surgeons (ESCRS). Paris, September 2004.
8. Calderón D, Kabat AG, Schinas Z, et al. Successful management of a central bacterial corneal ulcer with topical moxifloxacin and the importance of concurrent corticosteroid use. Presented at the 108th Annual Congress of the American Optometric Association. Dallas, TX, June 2005.
9. Wilhelmus KR. Indecision about corticosteroids for bacterial keratitis: An evidence-based update. *Ophthalmol*. 2002;109:835-842.
10. Lee SY, Laibson PR. Herpetic Eye Disease Study Group. Medical management of herpes simplex ocular infections. *Int Ophthalmol Clin*. 1996;36:85-97.
11. Oral acyclovir for herpes simplex virus eye disease: effect on prevention of epithelial keratitis and stromal keratitis. Herpetic Eye Disease Study Group. *Arch Ophthalmol*. 2000;118:1030-1036.

By Glenn S. Corbin, O.D.



# Evolutions in Ocular Allergy

**Learning how to prescribe ocular allergy medications proactively is the key to better outcomes for patients.**

The incidence of allergy in the United States ranges anywhere from 25% to 50%, depending on the source cited. Regardless of the actual number, ocular allergy significantly affects the quality of life and activities of daily living.<sup>1,2</sup> Allergy medication users rated “itchy eyes” as the third most prominent symptom in a Gallup study in 2005, but only 30% of ocular allergy prescriptions are written by primary care physicians.<sup>3</sup>

Current prescription treatment options offer rapid relief of signs and symptoms and allow individuals to lead more comfortable and productive lives. We didn’t always have such effective agents, so many of our patients continue to self-medicate with less effective over-the-counter (OTC) products.

This article will discuss the various allergic ocular conditions, the scientific basis of ocular allergy treatment and the importance of proactive prescribing, which is paramount to providing optimal patient care and ensuring your practice’s growth.

## What is ocular allergy?

We typically classify ocular allergy within four categories: allergic conjunctivitis, which can be seasonal (SAC) or perennial (PAC), giant papillary conjunctivitis (GPC), which is usually contact lens-related, vernal keratoconjunctivitis and atopic keratoconjunctivitis.

Seasonal or perennial allergic conjunctivitis, which represents about 90% of typically encountered allergy patients, is known to be a type I hypersensitivity IgE-mediated response.<sup>4,5</sup> This presentation is referred to as the early-phase allergic reaction, a result of mast cell (the pivotal element in ocular allergy) sensitization to environmental allergens followed by IgE-mast cell activation, with subsequent degranulation of the mast cell, and release of histamine and other preformed mediators. Increased histamine levels stimulate blood vessels, nerves and mucus-producing glands (via H1 receptor binding), resulting in the characteristic signs and symptoms of allergic conjunctivitis. In seasonal and perennial allergic conjunctivitis, clinical signs and symptoms, such as ocular

itching, conjunctival hyperemia, chemosis, lid edema and tearing, are a direct result of this early-phase reaction.

Giant papillary conjunctivitis is considered an immunological response or an overreaction of the body’s immune system to an allergen. It’s typically seen as a contact lens-related entity or a response to mechanical irritation, such as exposed sutures. Signs and symptoms may include uniform or giant papillae on the superior tarsus as well as palpebral conjunctival hyperemia and excess mucous discharge. In the contact lens wearer, the telltale symptom is usually lens displacement or decentration. Often GPC is asymptomatic and may go undiagnosed if lid eversion isn’t a routine part of your exam.

In vernal and atopic keratoconjunctivitis, more serious ocular allergy presentations seen less frequently, the allergic events are more complex. These are representative of late-phase allergy, which begins hours after the initial activation and involves additional inflammatory cells. Eosinophils, neutrophils, basophils and T lymphocytes infiltrate the conjunctival mucosa. Eosinophils in vernal keratoconjunctivitis and lymphocytes in atopic keratoconjunctivitis take on active roles in these diseases and are responsible for corneal damage such as keratitis, limbal infiltrates (trantas dots) and shield ulcers. Recurrence and prolongation of symptoms are a result of a variety of mediators released by these additional inflammatory cells. These represent potentially sight-threatening ocular allergy conditions.

The mast cell remains the pivotal element in allergic eye disease. The human conjunctiva has more than 50 million mast cells located in deeper tissue layers. During an allergic event, the mast cells migrate to more superficial layers. Mast cells can be degranulated by either immune or mechanical stimuli leading to the release of histamine and other pro-inflammatory mediators. This is the process that we must address in our treatment.

## Drug selection

Documented in the literature since 1960, it’s well known that antihistamines have a biphasic effect on cell

or biological membranes.<sup>6</sup> Antihistamines cause inhibition of secretion or in the case of mast cells, degranulation at low concentrations, then actually stimulate mast cell degranulation and histamine release at higher concentrations. This histamine release is believed to be due to non-specific cell membrane damage (all cells, including corneal epithelium), possibly from a disruption in membrane integrity. This is of interest to those providing eye care because the commercially available concentrations of antihistamines applied to the eye are in the ranges that can disrupt cell membranes, with the exception of olopatadine hydrochloride ophthalmic solution 0.1% (Patanol, Alcon Laboratories Inc.) or 0.2% (Pataday, Alcon Laboratories Inc.), as demonstrated in Figure 1.

Remember that ocular allergy involves more than just histamine, therefore a potent and long-lasting mast cell stabilizer is an important component in effectively treating this group of diseases. Figure 2 outlines the risk for tissue damage when mast cell stabilization is left unattended and a late-phase effect occurs.

### Treatment options

Our ultimate obligation to our patients is to offer them the most effective treatment available. In doing so, we must understand the different ways in which the drugs work and the dosing schedules that are required to maintain 24-hour comfort.

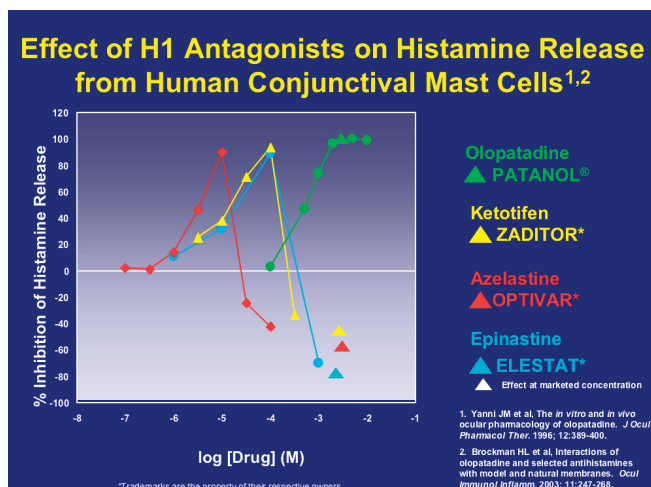


Figure 1. Most commercially available concentrations of ocular antihistamines (with the exception of a few) disrupt cell membranes.

OTC drugs that contain vasoconstrictors offer only short-term relief of conjunctival hyperemia, and they must be dosed every 2 to 4 hours. There's risk of potential toxicity from frequent dosing and preservative-related damage caused by benzalkonium chloride (BAK). Contact lens patients would certainly need to interrupt their wearing schedules if relying on these products for relief. Patients

often complain of discomfort on instillation with these drops and may experience tachyphylaxis or possible rebound hyperemia. These products include Opcon-A (Bausch & Lomb), Visine-A (Pfizer) and Naphcon-A

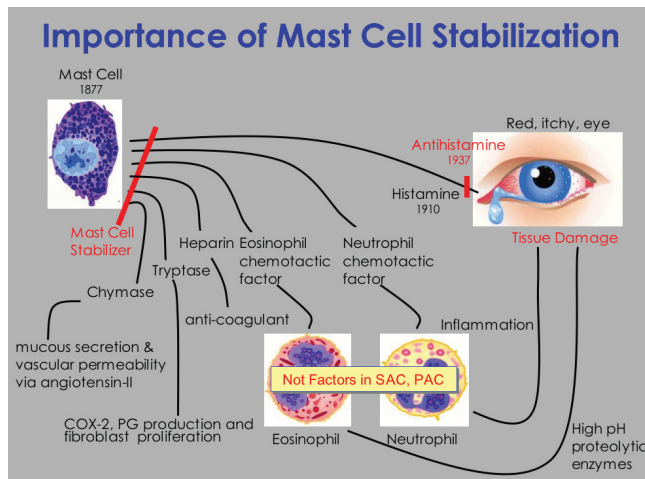


Figure 2. A long-lasting mast cell stabilizer is a must for allergy sufferers. This diagram outlines the risk for ocular tissue damage when mast cell stabilization is left unattended and a late-phase effect occurs.

(Alcon Laboratories Inc.), all of which contain an H1-receptor antihistamine (either antazoline or pheniramine) and a vasoconstrictor (either naphazoline or tetrahydrozoline).

The only pure antihistamine available by prescription is emadastine difumarate ophthalmic solution 0.05% (Emadine, Alcon Laboratories Inc.). As discussed earlier, the need for mast cell stabilization is important for allergy sufferers, something lacking in a pure antihistamine. Emadine requires q.i.d. dosing, which is a limiting factor as well, but it does offer immediate relief.

Because of the desire for fast symptom relief, pure mast cell stabilizers fall short. They're effective for allergy prevention but not for acute allergy events and, therefore, shouldn't be employed as first-line therapy. Nedocromil sodium ophthalmic solution 2% (Alocril, Allergan Inc.) and pemirolast potassium ophthalmic solution 0.1% (Alamast, Santen Inc.), the newest mast cell stabilizers, require b.i.d. dosing, whereas the older formulations, including lodoxamide tromethamine ophthalmic solution 0.1% (Alomide, Alcon Laboratories Inc.) and cromolyn sodium ophthalmic solution 4% require q.i.d. dosing.

The only nonsteroidal anti-inflammatory approved for ocular allergy is ketorolac tromethamine ophthalmic solution 0.4% (Acular LS, Allergan Inc.). This drug requires q.i.d. dosing, offers limited effectiveness in treating the signs and symptoms of ocular allergy and isn't prescribed often for this group of diseases.



The lone steroid approved for ocular allergy is loteprednol etabonate ophthalmic suspension 0.2% (Alrex, Bausch & Lomb). Steroid intervention is typically warranted with severe, initial case presentations as adjunctive therapy or to quell late-phase tissue inflammation. Dosing is q.i.d. and pediatric use is limited to children age 12 and older.

Based on proven clinical efficacy and the ability to offer both acute relief and prophylaxis, first-line therapy should be selected from the antihistamine/mast cell stabilizer dual-action drug group. These include ketotifen fumarate ophthalmic solution 0.025% (Zaditor, Novartis), epinastine HCl ophthalmic solution 0.05% (Elestat, Allergan Inc.), azelastine hydrochloride ophthalmic solution 0.05% (Optivar, MedPointe Inc.), olopatadine 0.1% and olopatadine 0.2%. All of these drugs require b.i.d. dosing with the exception of olopatadine hydrochloride ophthalmic solution, which only requires once-daily dosing.

The combination of dosing and consistent mast-cell stabilization (doesn't exhibit biphasic effect) renders olopatadine hydrochloride as a convenient choice for all of our patients and, especially, our contact lens allergy sufferers. The strong mast-cell stabilization capability of olopatadine hydrochloride makes it a superior choice compared with OTC combo products.<sup>7</sup> Less frequent dosing is associated with higher compliance rates. And increased compliance that's associated with once-daily dosing has been shown to provide patients with better symptom control,<sup>8,9</sup> quality of life and satisfaction.<sup>8</sup>

### More than just prescribing

Managing allergy patients who also have an ocular component requires proactive skills and a desire to do more than just ocular allergy prescribing. As the primary gatekeepers of eye care, our optometric responsibilities include developing a relationship with competent specialists to further enhance the quality of life for our patients. Get to know your local allergists, ear, nose and throat specialists, dermatologists and rheumatologists because many of your ocular allergy patients could benefit from an initial diagnosis or modifications in their systemic allergy treatment, or they may be candidates for immunotherapy.

Be certain to ask all of your patients if they experience itching, redness, tearing or other signs and symptoms any time of the year. This assures that you'll diagnose "out of season" allergy during your patient's routine visit to your office. Issue a prescription at that visit so the patient can fill it and have the medication available when symptoms begin.

### Growing your practice

Considering most ocular allergy prescriptions are written by non-eyecare professionals, the opportunity to grow your allergy practice is significant. Prescribing for ocular allergy, especially in children and young contact lens patients, sends a message to patients that optometrists have prescriptive authority and should be their first choice for seeking medical eye care as other pathologies arise down the road.

The American Society for Aesthetic Plastic Surgery revealed that more than \$12 billion was spent on 11.5 million cosmetic procedures (surgical and nonsurgical) in 2006.<sup>10</sup> These statistics clearly indicate that patients expect their doctors to prescribe whatever therapies are appropriate to enhance the way they look and feel. Allergy-associated red, teary and itchy eyes certainly demand prompt and long-term relief. And optometrists are in the best position to address this population. **OM**

Glenn S. Corbin, O.D., is a partner in a private practice in Reading, Pa. He is a member of the adjunct faculty and a preceptor for the externship program at the Pennsylvania College of Optometry. He has conducted clinical trials for glaucoma, allergy, dry eye, anti-infectives and contact lens materials and solutions.

#### References

- Berger W, Abelson MB, Gomes PJ, et al. Effects of adjuvant therapy with 0.1% olopatadine hydrochloride ophthalmic solution on quality of life in patients with allergic rhinitis using systemic or nasal therapy. *Ann Allergy Asthma Immunol.* 2005;95:361-371.
- Pitt AD, Smith AF, Lindsell L, et al. Economic and quality-of-life impact of seasonal allergic conjunctivitis in Oxfordshire. *Ophthalmic Epidemiol.* 2004;11:17-33.
- Gallup Study of Allergies, 2005, Phase II report.
- Allansmith MR. *The Eye and Immunology.* St Louis: C.V. Mosby, 1982:118-124.
- Abelson MB. *Allergic Diseases of the Eye.* Philadelphia, PA: W.B. Saunders Co; 2000.
- Mota I, da Silva W. The anti-anaphylactic and histamine-releasing properties of the antihistamines. Their effect on mast cells. *Br J Pharmacol Chemother.* 1960;15:396-404.
- Brockman H, Graff G, Spellman J, Yanni J. A comparison of the effects of olopatadine and ketotifen on model membranes. *Acta Ophthalmol Scand Suppl.* 2000;230:10-15.
- Richter A, Anton SE, Koch P, Dennett SL. The impact of reducing dose frequency on health outcomes. *Clin Ther.* 2003;25:2307-2335.
- Claxton AJ, Cramer J, Pierce C. A systematic review of the associations between dose regimens and medication compliance. *Clin Ther.* 2001;23:1296-1310.
- American Society for Aesthetic Plastic Surgery, March 2007. [www.surgery.org/press/news-release.php?iid=465](http://www.surgery.org/press/news-release.php?iid=465). Last accessed August 15, 2007.

# How to Earn Your CE Credits

This continuing education course is made possible by an unrestricted educational grant from Alcon. Blacken the most appropriate answers on the mail-in card, and mail it no later than March 31, 2009. Please allow 6 to 8 weeks to receive your certificate.

If you pass this course, you will receive credit from the Continuing Education department at The New England College of Optometry. The Council on Optometric Practitioner Education (COPE) has approved this course for one continuing education credit. The COPE I.D. number is 19847-AS.

1. Which eye condition is often a concurrent disorder with glaucoma because the risk for both conditions increases with age?
  - a. Dry eye
  - b. Blepharitis
  - c. Corneal neovascularization
  - d. Cataracts
2. In addition to age, glaucoma and ocular surface disorders share some risk factors, such as smoking, use of systemic medications and which of the following?
  - a. Alcohol consumption
  - b. Autoimmune disease
  - c. Obesity
  - d. Underlying vascular or inflammatory disease
3. Long-term use of preserved topical anti-glaucoma drugs has been shown to compromise the conjunctiva and which of the following?
  - a. Meibomian gland function
  - b. Goblet cells
  - c. Lacrimal gland function
  - d. Ciliary body
4. Which of the following tests does *not* help distinguish between aqueous layer tear deficient dry eye and evaporative dry eye?
  - a. Fluorescein and lissamine green staining
  - b. Rose bengal staining
  - c. Schirmer test 1
  - d. Meibomian gland evaluation
5. In normal- to dry-eyed individuals, the pH of tears varies within what range?
  - a. 7.5 to 7.9
  - b. 8.0 to 8.5
  - c. 8.6 to 9.0
  - d. 9.2 to 9.7
6. Abelson and colleagues evaluated the effects of Systane and Optive on tear film break-up time over an interval of how many minutes?
  - a. 10
  - b. 30
  - c. 60
  - d. 90
7. Symptoms of mild, nonspecific viral conjunctivitis include mild photophobia and which of the following?
  - a. Persistent tearing
  - b. Thick serous discharge
  - c. Diffuse bulbar hyperemia
  - d. Chemosis
8. Which symptom is considered the hallmark of bacterial conjunctivitis?
  - a. Punctate epitheliopathy of the cornea
  - b. Episcleral vessels
  - c. Accumulation of a thick, yellowish mucopurulent discharge
  - d. Acute hyperemia
9. The human conjunctiva has more than how many mast cells located in deeper tissue layers?
  - a. 20 million
  - b. 30 million
  - c. 40 million
  - d. 50 million
10. Based on proven clinical efficacy and the ability to offer both acute relief and prophylaxis, first-line therapy for ocular allergies should be selected from which of the following drug groups?
  - a. Antihistamines
  - b. Mast cell stabilizers
  - c. Antihistamine/mast cell stabilizer
  - d. Non-steroidal anti-inflammatories